



PATIENT

Victoria Nappi

PRESENTING CLINICAL SIGNS

History: History of CVD with mild PAH. Doing well.
-Current medications: Enalapril, Pimobendan, Lomotil.

SPECIES

Canine

ECHOCARDIOGRAM FINDINGS

2D, m-mode, color flow and doppler imaging is available. The mitral valve is diffusely thickened with prolapse into the left atrial lumen. There is severe eccentric mitral regurgitation present. The MR velocity is normal. There is severe left atrial enlargement. There is mild left ventricular dilation. Left ventricular systolic function is hyperdynamic. Mild right atrial and ventricular dilation (subjective). Mild thickening of the tricuspid valve with mild TR. Velocity consistent with early pulmonary hypertension. There is normal systolic flow velocity across the aortic valve. The aortic valve appears trileaflet with normal mobility. The main pulmonary artery is normal in diameter. The pulmonic valve is normal in appearance. Trace pulmonic insufficiency. No pericardial/pleural effusion or cardiac masses are seen.

BREED

Pomeranian

SEX

Female Spayed

CARDIAC CHART

AGE

13 years

WEIGHT

12lbs

INTERPRETED BY

Maggie Machen Lamy,
DVM, DACVIM
(Cardiology)

CANINE CARDIAC PARAMETERS	MR VMAX (m/s)	TR VMAX (m/s)	LA/AO (Boon method)	LA/AO (Heart Base; Swe)	FS (%)	EF (%)	EPSS (cm)
NORMAL PARAMETER	4.5-5.5	<2.7	1.3	<1.6	28-40	40-100	<0.6
PATIENT	5.7	3.3	2.0	2.4	59	89	0.14
CANINE CARDIAC PARAMETERS	HR (BPM)	AV VMAX (m/s)	PV MAX (m/s)	BODY WEIGHT (kg)	LA 2D short axis Base view (cm)	LVIDd Avg; 2D and m-mode short axis (cm)	LVIDs Avg; 2D and m-mode short axis (cm)
NORMAL PARAMETER	50-100	0.7-1.7	0.7-1.6	BELOW	BELOW	BELOW	BELOW
PATIENT	160		0.9	5.4	3.0	3.0	1.7
*Normal chamber parameters expressed as a mean value (SD)				3	1.27 (5.3)	2.46 (2.46)	1.36 (5.5)
BODY WEIGHT DEPENDENT PARAMETERS				5	1.40 (4.5)	2.74 (5.2)	1.60 (4.7)
<i>*Note: All measurements based upon multi-modal images and methods. An average value is reported.</i>				10	1.50 (3.8)	3.27 (3.5)	2.06 (3.1)
				15	1.83 (2.0)	3.71 (2.4)	2.43 (2.1)
				20	2.02 (1.9)	4.14 (2.2)	2.80 (2.0)
				25	2.18 (2.4)	4.48 (2.9)	3.10 (2.5)
				30	2.33 (3.3)	4.83 (3.9)	3.39 (3.4)
				35	2.48 (4.3)	5.17 (5.0)	3.69 (4.5)
				40	2.62 (5.2)	5.48 (6.1)	3.96 (5.4)
				50	2.88 (7.1)	6.07 (8.3)	4.46 (7.4)

INTERPRETATION OF THE FINDINGS & FURTHER RECOMMENDATIONS

Chronic degenerative valve disease causing severe mitral and mild tricuspid regurgitation. Compared to what is reported from the prior study, these findings are likely similar. The LA is significantly dilated indicating a high risk for clinical signs going forward. Mild pulmonary hypertension is noted, which is likely secondary to chronic LA pressure elevation. No additional concurrent issues such as systolic dysfunction are documented.

INVOICE

25146

DATE

7/5/22

With this degree of left heart changes, the risk for spontaneous congestive heart failure is elevated and continued cardiac supportive medications are indicated as below, including addition of Spironolactone for long-term benefit. Assessment of progression in the future will help predict long term outcome, however prognosis is guarded at this stage (late B2). Unfortunately, the

HOSPITAL NAME

All Creatures Great and Small

REFERRING VET

Dr. Ashmore



PATIENT

Victoria Nappi

patient will always be at risk for recurrent CHF, development of arrhythmias/LA tear, syncope and/or sudden death in the future.

SPECIES

Canine

Close monitoring for development of associated clinical signs (development of a cough, labored breathing, exercise intolerance or worsening collapse episodes) is recommended. Monitoring of sleeping breathing rates is recommended as the best way to screen for CHF at home.

BREED

Pomeranian

Elective anesthesia is not advised, as there is high risk for complication. If necessary, cardiac protective drug choices (opioid/benzodiazepine premedication, propofol or alfaxalone induction, iso or sevoflurane gas) are recommended. Pre-oxygenate for 5-10 minutes prior to induction and recover in O2 cage. Monitor for arrhythmias, hypotension, and hypoxia both intra and post-operatively and intervene as necessary. Moderate IV fluid restriction is recommended to avoid fluid overload. Avoid heart rate stimulating drugs such as atropine unless clinically indicated.

SEX

Female Spayed

Omega fatty acid supplementation and mild salt restriction may also be of some long-term benefit.

AGE

13 years

PLAN

A screening BP is recommended. Administer Pimobendan 0.3mg/kg PO q12h. Administer ACE-I (benazepril or enalapril) 0.5mg/kg PO q12h. Institute spironolactone 1-2mg/kg PO q12h.

WEIGHT

12lbs

Monitor renal values in 1-2 weeks, then every 3-4 months lifelong to ensure tolerance of medications.

INTERPRETED BY

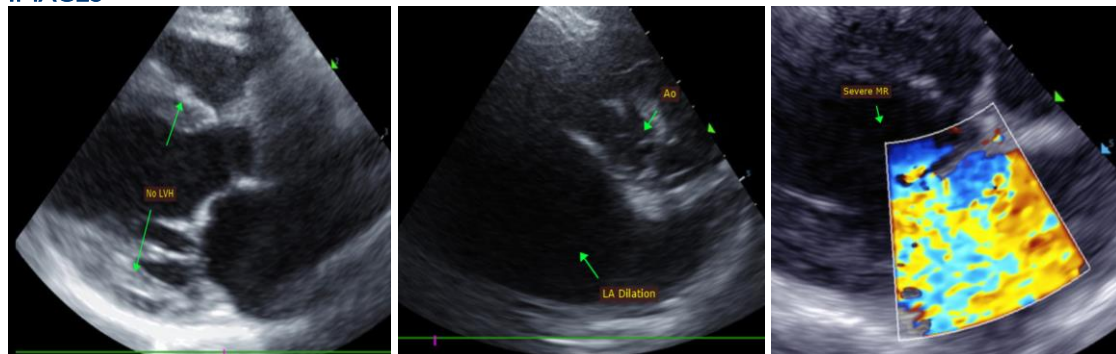
Maggie Machen Lamy,
DVM, DACVIM
(Cardiology)

A recheck echocardiogram is recommended in 4-6 months to screen for progression, sooner if clinical signs arise.

IMAGING PERFORMED BY

Jessica Miller

IMAGES



HOSPITAL NAME

All Creatures Great
and Small

REFERRING VET

Dr. Ashmore

The information and recommendations provided are based on the images presented by the referring veterinarian. No evaluation can be communicated regarding pathology that was not visible in the image/video clips provided.

INVOICE

25146

Thank you for this referral. This report was generated using transcription software, and minor dictation errors may be present. If the clinical or image interpretation does not parallel your findings or if I can be of any further assistance, please contact me.

DATE

7/5/22

Maggie Machen Lamy, DVM
Diplomate of the American College of Veterinary Internal Medicine (Cardiology)
info@sonopath.com